




- **Understanding Malocclusions in Everyday Orthodontics**

Understanding Malocclusions in Everyday Orthodontics Exploring Overbites and Their Impact on Oral Health Examining Crossbites and Jaw Alignment Identifying Signs of Underbites in Young Patients Misaligned Teeth and the Role of Early Intervention Correcting Crowding with Current Orthodontic Care Addressing Spacing Issues for Dental Harmony Recognizing Early Orthodontic Warning Signs Differentiating Structural and Functional Issues Managing Open Bites for Long Term Stability Factors Influencing Tooth Alignment Over Time Observing Bite Patterns for Early Intervention Strategies

- **Overview of Traditional Braces in Orthodontics**

Overview of Traditional Braces in Orthodontics How Clear Aligners Reshape Smiles The Purpose of Retainers After Treatment Self Ligating Brackets and Their Advantages Comparing Lingual Braces and External Options Approaches to Early Interceptive Orthodontics Exploring Palatal Expanders for Jaw Development Enhancing Dental Stability Through Headgear Regular Adjustments and Why They Matter Transitioning from Braces to Retainers Understanding Relapse in Orthodontic Treatment Selecting an Orthodontic Method for Different Needs

- **About Us**



Addressing Spacing Issues for Dental Harmony

Types of Malocclusions: Overview of common types such as overbite, underbite, and crossbite in pediatric patients.

Types of Malocclusions: Overview of common types such as overbite, underbite, and crossbite in pediatric patients.

When it comes to children's dental health, spacing issues are a common concern that can significantly impact dental harmony. These spacing irregularities often manifest as gaps between teeth, known as diastemas, or as crowded teeth where there is insufficient room for proper alignment. Interceptive orthodontics can guide facial and jaw development Early orthodontic intervention patient. Understanding these issues is crucial for ensuring the long-term health and aesthetics of a child's smile.

One of the most frequently observed spacing issues in children is the presence of diastemas. These gaps can occur due to a variety of reasons, including the premature loss of baby teeth, which can lead to neighboring teeth shifting into the empty space. While some diastemas may close naturally as permanent teeth erupt, persistent gaps may require orthodontic intervention to prevent future complications such as misalignment or speech difficulties.

On the other end of the spectrum, crowded teeth can also pose significant challenges. Crowding often results from a discrepancy between the size of the jaw and the size of the teeth. When there is not enough space for all the teeth to align properly, they can become twisted or overlap, leading to aesthetic concerns and functional problems like difficulty in cleaning the teeth properly, which can increase the risk of decay and gum disease.

The impact of these spacing issues on dental harmony cannot be overstated. Dental harmony refers to the ideal alignment and spacing of teeth, which contributes to both the aesthetic appeal and the functional efficiency of the mouth. When teeth are well-spaced and aligned, it facilitates proper biting, chewing, and speaking. Moreover, a harmonious smile can boost a child's confidence and self-esteem, which are crucial during their developmental years.

Addressing spacing issues in children early on is vital for achieving and maintaining dental harmony. Orthodontic treatments, such as braces or clear aligners, can be employed to correct these issues. In some cases, space maintainers may be used to hold space for permanent teeth after the premature loss of baby teeth. Additionally, regular dental check-ups and consultations with an orthodontist can help monitor the development of a child's teeth and intervene as necessary.

In conclusion, common spacing issues in children's teeth, such as diastemas and crowding, can have a profound impact on dental harmony. By understanding these issues and seeking timely intervention, parents and caregivers can help ensure that their children enjoy the benefits of a healthy, harmonious smile that lasts a lifetime.

Early orthodontic interventions play a crucial role in addressing spacing problems in young children, paving the way for dental harmony. These interventions, often initiated when a child's primary teeth are still in place, aim to correct issues before they become more complex and costly to treat in adulthood.

One common spacing problem in young children is the presence of gaps between teeth, which can be caused by a variety of factors, such as thumb sucking, tongue thrusting, or the premature loss of baby teeth. If left unaddressed, these gaps can lead to misalignment of permanent teeth, bite problems, and even speech difficulties.

Early orthodontic interventions can help prevent these issues by guiding the growth and development of the jaw and teeth. For example, a child with a narrow upper jaw may benefit from a palatal expander, which gradually widens the jaw to create more space for teeth to come in properly. Similarly, a space maintainer can be used to hold the space for a permanent tooth if a baby tooth is lost prematurely.

Another benefit of early intervention is that it can reduce the need for more invasive treatments later on. By addressing spacing problems at a young age, orthodontists can often guide teeth into their proper positions without the need for extraction or extensive orthodontic work.

Moreover, early orthodontic interventions can boost a child's self-confidence by improving the appearance of their smile. Children who feel good about their teeth are more likely to take better care of them, leading to improved oral health overall.

In conclusion, early orthodontic interventions are essential for addressing spacing problems in young children and promoting dental harmony. By guiding the growth and development of teeth and jaws, these interventions can prevent more serious issues down the line, reduce the need for invasive treatments, and boost a child's self-confidence. Parents should consult with an orthodontist if they notice any spacing issues in their child's teeth to ensure the best possible outcome for their child's oral health.

Early Detection and Diagnosis:

The importance of regular dental check-ups for identifying

malocclusions in children.

In the quest for dental harmony, addressing spacing issues plays a pivotal role. The misalignment of teeth, often manifesting as gaps or overcrowding, can not only affect the aesthetic appeal of one's smile but also lead to functional problems such as difficulty in chewing and maintaining oral hygiene. This is where the use of braces and aligners comes into play, offering effective solutions to correct spacing issues and achieve optimal dental alignment.

Braces, traditionally made of metal or ceramic, work by applying continuous pressure on the teeth to move them into the desired position. They consist of brackets bonded to each tooth and connected by a wire that can be adjusted periodically by an orthodontist. This gradual process helps in closing gaps and aligning teeth in a way that enhances both the function and appearance of the smile. For those concerned about the visibility of braces, clear or tooth-colored options are available, blending more seamlessly with the natural teeth.

On the other hand, aligners represent a more modern approach to correcting spacing issues. Made from clear plastic, these removable devices are custom-fitted to the patient's teeth and are changed every few weeks to reflect the gradual movement of the teeth. Aligners offer the advantage of being nearly invisible, making them a popular choice among adults and teens who are self-conscious about wearing traditional braces. Additionally, their removable nature allows for easier cleaning and the ability to eat without restrictions, enhancing the overall experience of orthodontic treatment.

Both braces and aligners are effective in correcting spacing issues, but the choice between them depends on individual needs and preferences. Factors such as the severity of the spacing, the patient's age, lifestyle, and aesthetic concerns all play a role in deciding the most suitable treatment. Regardless of the method chosen, the ultimate goal remains the same: to achieve dental harmony by correcting spacing issues and ensuring optimal alignment.

In conclusion, braces and aligners serve as essential tools in the journey towards a well-aligned smile. By addressing spacing issues, they not only enhance the aesthetic appeal but also contribute to better oral health and function. As such, they are indispensable in the pursuit of dental harmony, offering personalized solutions that cater to the diverse needs of patients seeking to improve their smiles.

Orthodontic Treatment Options for Kids: Discussing braces, aligners, and other corrective measures suitable for young patients.

Regular dental check-ups and monitoring play a crucial role in achieving dental harmony, particularly during orthodontic treatment aimed at addressing spacing issues. These routine visits are essential not only for maintaining oral health but also for ensuring the success of orthodontic interventions.

Orthodontic treatment, which often involves the use of braces, aligners, or other devices to correct spacing problems, requires meticulous monitoring to track progress and make necessary adjustments. Regular check-ups allow orthodontists to assess the movement of teeth, ensuring they are shifting according to plan. This is vital in preventing complications such as uneven

spacing or misalignment, which could compromise the final outcome.

Moreover, these appointments provide an opportunity for dental professionals to identify and address any issues that may arise during treatment. For instance, brackets may become loose, or wires might need adjustments. Prompt attention to these matters can prevent delays and ensure the treatment remains on track.

Beyond the mechanical aspects, regular dental visits also focus on maintaining overall oral health. Orthodontic appliances can make it challenging to clean teeth effectively, increasing the risk of plaque buildup and gum disease. During check-ups, dental hygienists can clean areas that are difficult to reach at home and offer personalized advice on oral hygiene practices tailored to the patient's specific needs.

Furthermore, these visits allow for the early detection of any dental issues unrelated to the orthodontic treatment, such as cavities or gum inflammation. Addressing these problems promptly can prevent them from interfering with the orthodontic process and contributing to further spacing issues.

In essence, regular dental check-ups and monitoring are indispensable components of orthodontic treatment aimed at achieving dental harmony. They ensure that spacing issues are addressed effectively, while also safeguarding the overall health of the teeth and gums. By committing to these routine visits, patients can enhance their chances of achieving a beautifully aligned and healthy smile.

The Role of Parents in Orthodontic Care: How parents can support their child's orthodontic treatment and encourage good oral habits.

As a parent, supporting your child's orthodontic treatment and maintaining good oral hygiene are crucial steps in addressing spacing issues for dental harmony. Orthodontic treatment, such as braces or aligners, can correct misaligned teeth and improve overall oral health, but it requires diligent care and support from both the child and the parents.

First and foremost, it's essential to encourage your child to maintain excellent oral hygiene throughout their orthodontic treatment. This means brushing their teeth at least twice a day, using fluoride toothpaste, and spending extra time cleaning around brackets and wires. A soft-bristled toothbrush or an electric toothbrush can help remove plaque and food particles more effectively. Additionally, flossing daily with the help of floss threaders or orthodontic flossers is crucial to prevent gum disease and tooth decay.

Parents can also support their child's orthodontic treatment by ensuring they attend all scheduled appointments with their orthodontist. Regular check-ups and adjustments are necessary to monitor progress and make any necessary changes to the treatment plan. If your child is experiencing discomfort or issues with their braces, encourage them to communicate openly with their orthodontist, as timely adjustments can make a significant difference in their overall experience.

Another way to support your child's orthodontic journey is by helping them make healthy food choices. Sticky, hard, or sugary foods can damage braces or lead to tooth decay, so it's best to avoid these items. Instead, encourage your child to eat soft, nutritious foods like fruits, vegetables, lean proteins, and dairy products. If they do indulge in sugary treats, remind them to brush their teeth immediately afterward to minimize the risk of cavities.

Lastly, be patient and supportive throughout the orthodontic treatment process. It's normal for children to feel self-conscious about their appearance with braces, so offer them encouragement and remind them that the end result will be a beautiful, healthy smile. Celebrate milestones along the way, such as the removal of braces or the completion of aligner treatment, and praise your child for their dedication to their oral health.

By following these tips and working closely with your child's orthodontist, you can help them achieve dental harmony and maintain good oral hygiene throughout their orthodontic treatment. Remember, your support and guidance play a vital role in ensuring a successful outcome and a lifetime of healthy smiles.

Long-term Benefits of Early Orthodontic Intervention: How treating malocclusions in childhood can prevent more serious issues in adulthood.

Addressing spacing issues early can have profound long-term benefits for achieving a harmonious and healthy smile. When we consider dental harmony, it's not just about aesthetics; it's about ensuring the overall health and functionality of our teeth and jaws.

One of the primary advantages of early intervention in spacing issues is the prevention of more complex dental problems down the line. For instance, gaps between teeth can lead to food accumulation, increasing the risk of decay and gum disease. By addressing these spaces early, we can maintain better oral hygiene and reduce the likelihood of these conditions developing.

Moreover, correcting spacing issues early can positively impact the alignment of the teeth and jaws. Properly spaced teeth are less likely to shift out of place, which can prevent issues such as overbites, underbites, and crossbites. This not only contributes to a more aesthetically pleasing

smile but also ensures that the bite remains functional, reducing strain on the jaw muscles and temporomandibular joints.

Another significant benefit is the boost in self-confidence that comes with a harmonious smile. Children and adults alike can feel more comfortable and confident in social and professional settings when they are not self-conscious about their teeth. Early intervention can save individuals from the emotional and psychological impact of dental insecurities.


In terms of treatment, early action often means less invasive and more cost-effective solutions. Orthodontic treatments like braces or clear aligners can be more straightforward and efficient when applied early, potentially reducing the need for more extensive procedures like surgery or veneers later in life.

In conclusion, the long-term benefits of addressing spacing issues early are clear. From preventing dental diseases and ensuring proper alignment to enhancing self-esteem and optimizing treatment outcomes, early intervention is a crucial step toward achieving a harmonious and healthy smile. By prioritizing dental health from a young age, we set the foundation for a lifetime of confident smiles and optimal oral health.

About malocclusion

"Deep bite" and "Buck teeth" redirect here. For the village, see Deep Bight, Newfoundland and Labrador.

Malocclusion



Malocclusion in 10-year-old girl

Specialty

Dentistry

[Edit this on Wikidata](#)



Look up ***bucktooth*** in Wiktionary, the free dictionary.

In orthodontics, a **malocclusion** is a misalignment or incorrect relation between the teeth of the upper and lower dental arches when they approach each other as the jaws close. The English-language term dates from 1864;^[1] Edward Angle (1855–1930), the "father of modern orthodontics",^[2]^[3] *[need quotation to verify]* popularised it. The word derives from *mal-* 'incorrect' and *occlusion* 'the manner in which opposing teeth meet'.

The malocclusion classification is based on the relationship of the mesiobuccal cusp of the maxillary first molar and the buccal groove of the mandibular first molar. If this molar relationship exists, then the teeth can align into normal occlusion. According to Angle, malocclusion is any deviation of the occlusion from the ideal.^[4] However, assessment for malocclusion should also take into account aesthetics and the impact on functionality. If these aspects are acceptable to the patient despite meeting the formal definition of malocclusion, then treatment may not be necessary. It is estimated that nearly 30% of the population have malocclusions that are categorised as severe and definitely benefit from orthodontic treatment.^[5]

Causes

[edit]

The aetiology of malocclusion is somewhat contentious, however, simply put it is multifactorial, with influences being both genetic^[6]^[unreliable source?] and environmental.^[7] Malocclusion is already present in one of the Skhul and Qafzeh hominin fossils and other prehistoric human skulls.^[8]^[9] There are three generally accepted causative factors of malocclusion:

- Skeletal factors – the size, shape and relative positions of the upper and lower jaws. Variations can be caused by environmental or behavioral factors such as muscles of mastication, nocturnal mouth breathing, and cleft lip and cleft palate.
- Muscle factors – the form and function of the muscles that surround the teeth. This could be impacted by habits such as finger sucking, nail biting, pacifier and tongue thrusting^[10]
- Dental factors – size of the teeth in relation to the jaw, early loss of teeth could result in spacing or mesial migration causing crowding, abnormal eruption path or timings, extra teeth (supernumeraries), or too few teeth (hypodontia)

There is not one single cause of malocclusion, and when planning orthodontic treatment it is often helpful to consider the above factors and the impact they have played on malocclusion. These can also be influenced by oral habits and pressure resulting in malocclusion.^[11]^[12]

Behavioral and dental factors

[edit]

In the active skeletal growth,^[13] mouthbreathing, finger sucking, thumb sucking, pacifier sucking, onychophagia (nail biting), dermatophagia, pen biting, pencil biting, abnormal posture, deglutition disorders and other habits greatly influence the development of the face and dental arches.^[14]^[15]^[16]^[17]^[18] Pacifier sucking habits are also correlated with

otitis media.^[19]^[20] Dental caries, periapical inflammation and tooth loss in the deciduous teeth can alter the correct permanent teeth eruptions.

Primary vs. secondary dentition

[edit]

Malocclusion can occur in primary and secondary dentition.

In primary dentition malocclusion is caused by:

- Underdevelopment of the dentoalveolar tissue.
- Over development of bones around the mouth.
- Cleft lip and palate.
- Overcrowding of teeth.
- Abnormal development and growth of teeth.

In secondary dentition malocclusion is caused by:

- Periodontal disease.
- Overeruption of teeth.^[21]
- Premature and congenital loss of missing teeth.

Signs and symptoms

[edit]

Malocclusion is a common finding,^[22]^[23] although it is not usually serious enough to require treatment. Those who have more severe malocclusions, which present as a part of craniofacial anomalies, may require orthodontic and sometimes surgical treatment (orthognathic surgery) to correct the problem.

The ultimate goal of orthodontic treatment is to achieve a stable, functional and aesthetic alignment of teeth which serves to better the patient's dental and total health.^[24] The

symptoms which arise as a result of malocclusion derive from a deficiency in one or more of these categories.^[25]

The symptoms are as follows:

- Tooth decay (caries): misaligned teeth will make it more difficult to maintain oral hygiene. Children with poor oral hygiene and diet will be at an increased risk.
- Periodontal disease: irregular teeth would hinder the ability to clean teeth meaning poor plaque control. Additionally, if teeth are crowded, some may be more buccally or lingually placed, there will be reduced bone and periodontal support. Furthermore, in Class III malocclusions, mandibular anterior teeth are pushed labially which contributes to gingival recession and weakens periodontal support.
- Trauma to anterior teeth: Those with an increased overjet are at an increased risk of trauma. A systematic review found that an overjet of greater than 3mm will double the risk of trauma.
- Masticatory function: people with anterior open bites, large increased & reverse overjet and hypodontia will find it more difficult to chew food.
- Speech impairment: a lisp is when the incisors cannot make contact, orthodontics can treat this. However, other forms of misaligned teeth will have little impact on speech and orthodontic treatment has little effect on fixing any problems.
- Tooth impaction: these can cause resorption of adjacent teeth and other pathologies for example a dentigerous cyst formation.
- Psychosocial wellbeing: malocclusions of teeth with poor aesthetics can have a significant effect on self-esteem.

Malocclusions may be coupled with skeletal disharmony of the face, where the relations between the upper and lower jaws are not appropriate. Such skeletal disharmonies often distort sufferer's face shape, severely affect aesthetics of the face, and may be coupled with mastication or speech problems. Most skeletal malocclusions can only be treated by orthognathic surgery.^[citation needed]

Classification

[edit]

Depending on the sagittal relations of teeth and jaws, malocclusions can be divided mainly into three types according to Angle's classification system published 1899. However, there are also other conditions, e.g. *crowding of teeth*, not directly fitting into this classification.

Many authors have tried to modify or replace Angle's classification. This has resulted in many subtypes and new systems (see section below: *Review of Angle's system of classes*).

A deep bite (also known as a Type II Malocclusion) is a condition in which the upper teeth overlap the lower teeth, which can result in hard and soft tissue trauma, in addition to an effect on appearance.^[26] It has been found to occur in 15–20% of the US population.^[27]

An open bite is a condition characterised by a complete lack of overlap and occlusion between the upper and lower incisors.^[28] In children, open bite can be caused by prolonged thumb sucking.^[29] Patients often present with impaired speech and mastication.^[30]

Overbites

[edit]

This is a vertical measurement of the degree of overlap between the maxillary incisors and the mandibular incisors. There are three features that are analysed in the classification of an overbite:

- Degree of overlap: edge to edge, reduced, average, increased
- Complete or incomplete: whether there is contact between the lower teeth and the opposing teeth/tissue (hard palate or gingivae) or not.
- Whether contact is traumatic or atraumatic

An average overbite is when the upper anterior teeth cover a third of the lower teeth. Covering less than this is described as 'reduced' and more than this is an 'increased' overbite. No overlap or contact is considered an 'anterior open bite'.^[25]^[31]^[32]


Angle's classification method

[edit]




This section **may be too technical for most readers to understand**. Please help

improve it to make it understandable to non-experts, without removing the technical details. *(September 2023) (Learn how and when to remove this message)*



Class I with severe crowding and labially erupted canines



Class II molar relationship

Edward Angle, who is considered the father of modern orthodontics, was the first to classify malocclusion. He based his classifications on the relative position of the maxillary first molar.^[33] According to Angle, the mesiobuccal cusp of the upper first molar should align with the buccal groove of the mandibular first molar. The teeth should all fit on a line of occlusion which, in the upper arch, is a smooth curve through the central fossae of the posterior teeth and cingulum of the canines and incisors, and in the lower arch, is a smooth curve through the buccal cusps of the posterior teeth and incisal edges of the anterior teeth. Any variations from this resulted in malocclusion types. It is also possible to have different classes of malocclusion on left and right sides.

- **Class I** (Neutroccclusion): Here the molar relationship of the occlusion is normal but the incorrect line of occlusion or as described for the maxillary first molar, but the other teeth have problems like spacing, crowding, over or under eruption, etc.
- **Class II** (Distocclusion (retrognathism, overjet, overbite)): In this situation, the mesiobuccal cusp of the upper first molar is not aligned with the mesiobuccal groove of the lower first molar. Instead it is anterior to it. Usually the mesiobuccal cusp rests in between the first mandibular molars and second premolars. There are two subtypes:
 - Class II Division 1: The molar relationships are like that of Class II and the anterior teeth are protruded.
 - Class II Division 2: The molar relationships are Class II but the central are retroclined and the lateral teeth are seen overlapping the centrals.
- **Class III**: (Mesioocclusion (prognathism, anterior crossbite, negative overjet, underbite)) In this case the upper molars are placed not in the mesiobuccal groove but posteriorly to it. The mesiobuccal cusp of the maxillary first molar lies posteriorly to the mesiobuccal groove of the mandibular first molar. Usually seen as when the lower front teeth are more prominent than the upper front teeth. In this case the patient very often has a large mandible or a short maxillary bone.

Review of Angle's system of classes and alternative systems

[edit]

A major disadvantage of Angle's system of classifying malocclusions is that it only considers two dimensions along a spatial axis in the sagittal plane in the terminal occlusion, but occlusion problems can be three-dimensional. It does not recognise deviations in other spatial axes, asymmetric deviations, functional faults and other therapy-related features.

Angle's classification system also lacks a theoretical basis; it is purely descriptive. Its much-discussed weaknesses include that it only considers static occlusion, it does not account for the development and causes (aetiology) of occlusion problems, and it disregards the

proportions (or relationships in general) of teeth and face.^[34] Thus, many attempts have been made to modify the Angle system or to replace it completely with a more efficient one,^[35] but Angle's classification continues to be popular mainly because of its simplicity and clarity.^[citation needed]

Well-known modifications to Angle's classification date back to Martin Dewey (1915) and Benno Lischer (1912, 1933). Alternative systems have been suggested by, among others, Simon (1930, the first three-dimensional classification system), Jacob A. Salzmann (1950, with a classification system based on skeletal structures) and James L. Ackerman and William R. Proffit (1969).^[36]

Incisor classification

[edit]

Besides the molar relationship, the British Standards Institute Classification also classifies malocclusion into incisor relationship and canine relationship.

- Class I: The lower incisor edges occlude with or lie immediately below the cingulum plateau of the upper central incisors
- Class II: The lower incisor edges lie posterior to the cingulum plateau of the upper incisors
 - Division 1 – the upper central incisors are proclined or of average inclination and there is an increase in overjet
 - Division 2 – The upper central incisors are retroclined. The overjet is usually minimal or may be increased.
- Class III: The lower incisor edges lie anterior to the cingulum plateau of the upper incisors. The overjet is reduced or reversed.

Canine relationship by Ricketts

[edit]

- Class I: Mesial slope of upper canine coincides with distal slope of lower canine
- Class II: Mesial slope of upper canine is ahead of distal slope of lower canine
- Class III: Mesial slope of upper canine is behind to distal slope of lower canine

Crowding of teeth

[edit]

Dental crowding is defined by the amount of space that would be required for the teeth to be in correct alignment. It is obtained in two ways: 1) by measuring the amount of space required and reducing this from calculating the space available via the width of the teeth, or 2) by measuring the degree of overlap of the teeth.

The following criterion is used:[²⁵]

- 0–4mm = Mild crowding
- 4–8mm = Moderate crowding
- >8mm = Severe crowding

Causes

[edit]

Genetic (inheritance) factors, extra teeth, lost teeth, impacted teeth, or abnormally shaped teeth have been cited as causes of crowding. Ill-fitting dental fillings, crowns, appliances, retainers, or braces as well as misalignment of jaw fractures after a severe injury are also known to cause crowding.[²⁶] Tumors of the mouth and jaw, thumb sucking, tongue thrusting, pacifier use beyond age three, and prolonged use of a bottle have also been identified.[²⁶]

Lack of masticatory stress during development can cause tooth overcrowding.[³⁷][³⁸]
Children who chewed a hard resinous gum for two hours a day showed increased facial

growth.^[37] Experiments in animals have shown similar results. In an experiment on two groups of rock hyraxes fed hardened or softened versions of the same foods, the animals fed softer food had significantly narrower and shorter faces and thinner and shorter mandibles than animals fed hard food.^[37]^[39]^[failed verification]

A 2016 review found that breastfeeding lowers the incidence of malocclusions developing later on in developing infants.^[40]

During the transition to agriculture, the shape of the human mandible went through a series of changes. The mandible underwent a complex shape changes not matched by the teeth, leading to incongruity between the dental and mandibular form. These changes in human skulls may have been "driven by the decreasing bite forces required to chew the processed foods eaten once humans switched to growing different types of cereals, milking and herding animals about 10,000 years ago."^[38]^[41]

Treatment

[edit]

Orthodontic management of the condition includes dental braces, lingual braces, clear aligners or palatal expanders.^[42] Other treatments include the removal of one or more teeth and the repair of injured teeth. In some cases, surgery may be necessary.^[43]

Treatment

[edit]

Malocclusion is often treated with orthodontics,^[42] such as tooth extraction, clear aligners, or dental braces,^[44] followed by growth modification in children or jaw surgery (orthognathic surgery) in adults. Surgical intervention is used only in rare occasions. This may include surgical reshaping to lengthen or shorten the jaw. Wires, plates, or screws may be used to secure the jaw bone, in a manner like the surgical stabilization of jaw fractures. Very few people have "perfect" alignment of their teeth with most problems being minor

that do not require treatment.^[37]

Crowding

[edit]

Crowding of the teeth is treated with orthodontics, often with tooth extraction, clear aligners, or dental braces, followed by growth modification in children or jaw surgery (orthognathic surgery) in adults. Surgery may be required on rare occasions. This may include surgical reshaping to lengthen or shorten the jaw (orthognathic surgery). Wires, plates, or screws may be used to secure the jaw bone, in a manner similar to the surgical stabilization of jaw fractures. Very few people have "perfect" alignment of their teeth. However, most problems are very minor and do not require treatment.^[39]

Class I

[edit]

While treatment is not crucial in class I malocclusions, in severe cases of crowding can be an indication for intervention. Studies indicate that tooth extraction can have benefits to correcting malocclusion in individuals.^[45]^[46] Further research is needed as reoccurring crowding has been examined in other clinical trials.^[45]^[47]

Class II

[edit]

A few treatment options for class II malocclusions include:

1. Functional appliance which maintains the mandible in a postured position to influence both the orofacial musculature and dentoalveolar development prior to fixed appliance therapy. This is ideally done through pubertal growth in pre-adolescent children and the fixed appliance during permanent dentition .^[48] Different types of removable appliances include Activator, Bionatar, Medium opening activator, Herbst, Frankel and twin block appliance with the twin block being the most widely used one.^[49]
2. Growth modification through headgear to redirect maxillary growth
3. Orthodontic camouflage so that jaw discrepancy no longer apparent
4. Orthognathic surgery – sagittal split osteotomy mandibular advancement carried out when growth is complete where skeletal discrepancy is severe in anterior-posterior relationship or in vertical direction. Fixed appliance is required before, during and after surgery.
5. Upper Removable Appliance – limited role in contemporary treatment of increased overjets. Mostly used for very mild Class II, overjet due to incisor proclination, favourable overbite.

Class II Division 1

[edit]

Low- to moderate- quality evidence suggests that providing early orthodontic treatment for children with prominent upper front teeth (class II division 1) is more effective for reducing the incidence of incisal trauma than providing one course of orthodontic treatment in adolescence.^[50] There do not appear to be any other advantages of providing early treatment when compared to late treatment.^[50] Low-quality evidence suggests that, compared to no treatment, late treatment in adolescence with functional appliances is effective for reducing the prominence of upper front teeth.^[50]

Class II Division 2

[edit]

Treatment can be undertaken using orthodontic treatments using dental braces.^[51] While treatment is carried out, there is no evidence from clinical trials to recommend or discourage any type of orthodontic treatment in children.^[51] A 2018 Cochrane systematic review anticipated that the evidence base supporting treatment approaches is not likely to improve occlusion due to the low prevalence of the condition and the ethical difficulties in recruiting people to participate in a randomized controlled trials for treating this condition.^[51]

Class III

[edit]

The British Standard Institute (BSI) classify class III incisor relationship as the lower incisor edge lies anterior to the cingulum plateau of the upper incisors, with reduced or reversed over jet.^[52] The skeletal facial deformity is characterized by mandibular prognathism, maxillary retrognathism or a combination of the two. This effects 3–8% of UK population with a higher incidence seen in Asia.^[53]

One of the main reasons for correcting Class III malocclusion is aesthetics and function. This can have a psychological impact on the person with malocclusion resulting in speech and mastication problems as well. In mild class III cases, the patient is quite accepting of the aesthetics and the situation is monitored to observe the progression of skeletal growth.^[54]

Maxillary and mandibular skeletal changes during prepubertal, pubertal and post pubertal stages show that class III malocclusion is established before the prepubertal stage.^[55] One treatment option is the use of growth modification appliances such as the Chin Cap which has greatly improved the skeletal framework in the initial stages. However, majority of cases are shown to relapse into inherited class III malocclusion during the pubertal growth stage and when the appliance is removed after treatment.^[55]

Another approach is to carry out orthognathic surgery, such as a bilateral sagittal split osteotomy (BSSO) which is indicated by horizontal mandibular excess. This involves surgically cutting through the mandible and moving the fragment forward or backwards

for desired function and is supplemented with pre and post surgical orthodontics to ensure correct tooth relationship. Although the most common surgery of the mandible, it comes with several complications including: bleeding from inferior alveolar artery, unfavorable splits, condylar resorption, avascular necrosis and worsening of temporomandibular joint.[^{56]}

Orthodontic camouflage can also be used in patients with mild skeletal discrepancies. This is a less invasive approach that uses orthodontic brackets to correct malocclusion and try to hide the skeletal discrepancy. Due to limitations of orthodontics, this option is more viable for patients who are not as concerned about the aesthetics of their facial appearance and are happy to address the malocclusion only, as well as avoiding the risks which come with orthognathic surgery. Cephalometric data can aid in the differentiation between the cases that benefit from ortho-surgical or orthodontic treatment only (camouflage); for instance, examining a large group of orthognathic patient with Class III malocclusions they had average ANB angle of -3.57° (95% CI, -3.92° to -3.21°). [^{57]}

Deep bite

[edit]

The most common corrective treatments available are fixed or removal appliances (such as dental braces), which may or may not require surgical intervention. At this time there is no robust evidence that treatment will be successful.[^{51]}

Open bite

[edit]

An open bite malocclusion is when the upper teeth don't overlap the lower teeth. When this malocclusion occurs at the front teeth it is known as anterior open bite. An open bite is difficult to treat due to multifactorial causes, with relapse being a major concern. This is

particularly so for an anterior open bite.^[58] Therefore, it is important to carry out a thorough initial assessment in order to obtain a diagnosis to tailor a suitable treatment plan.^[58] It is important to take into consideration any habitual risk factors, as this is crucial for a successful outcome without relapse. Treatment approach includes behavior changes, appliances and surgery. Treatment for adults include a combination of extractions, fixed appliances, intermaxillary elastics and orthognathic surgery.^[30] For children, orthodontics is usually used to compensate for continued growth. With children with mixed dentition, the malocclusion may resolve on its own as the permanent teeth erupt. Furthermore, should the malocclusion be caused by childhood habits such as digit, thumb or pacifier sucking, it may result in resolution as the habit is stopped. Habit deterrent appliances may be used to help in breaking digit and thumb sucking habits. Other treatment options for patients who are still growing include functional appliances and headgear appliances.

Tooth size discrepancy

[edit]

Identifying the presence of tooth size discrepancies between the maxillary and mandibular arches is an important component of correct orthodontic diagnosis and treatment planning.

To establish appropriate alignment and occlusion, the size of upper and lower front teeth, or upper and lower teeth in general, needs to be proportional. Inter-arch tooth size discrepancy (ITSD) is defined as a disproportion in the mesio-distal dimensions of teeth of opposing dental arches. The prevalence is clinically significant among orthodontic patients and has been reported to range from 17% to 30%.^[59]

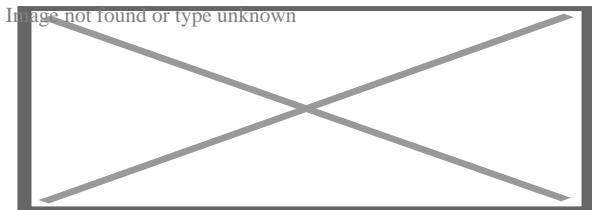
Identifying inter-arch tooth size discrepancy (ITSD) before treatment begins allows the practitioner to develop the treatment plan in a way that will take ITSD into account. ITSD corrective treatment may entail demanding reduction (interproximal wear), increase (crowns and resins), or elimination (extractions) of dental mass prior to treatment finalization.^[60]

Several methods have been used to determine ITSD. Of these methods the one most commonly used is the Bolton analysis. Bolton developed a method to calculate the ratio between the mesiodistal width of maxillary and mandibular teeth and stated that a correct and harmonious occlusion is possible only with adequate proportionality of tooth sizes.^[60] Bolton's formula concludes that if in the anterior portion the ratio is less than 77.2% the lower teeth are too narrow, the upper teeth are too wide or there is a combination of both. If the ratio is higher than 77.2% either the lower teeth are too wide, the upper teeth are too narrow or there is a combination of both.^[59]

Other conditions

[edit]

Further information: Open bite malocclusion



Open bite treatment after eight months of braces.

Other kinds of malocclusions can be due to or horizontal, vertical, or transverse skeletal discrepancies, including skeletal asymmetries.

Increased vertical growth causes a long facial profile and commonly leads to an open bite malocclusion, while decreased vertical facial growth causes a short facial profile and is commonly associated with a deep bite malocclusion. However, there are many other more common causes for open bites (such as tongue thrusting and thumb sucking) and likewise for deep bites.^{[61][62][63]}

The upper or lower jaw can be overgrown (macrognathia) or undergrown (micrognathia).^{[62][61][63]} It has been reported that patients with micrognathia are also affected by retrognathia (abnormal posterior positioning of the mandible or maxilla relative to the facial structure).^[62] These patients are majorly predisposed to a class II malocclusion. Mandibular macrognathia results in prognathism and predisposes patients to a class III malocclusion.^[64]

Most malocclusion studies to date have focused on Class III malocclusions. Genetic studies for Class II and Class I malocclusion are more rare. An example of hereditary mandibular prognathism can be seen amongst the Hapsburg Royal family where one third of the affected individuals with severe class III malocclusion had one parent with a similar phenotype [⁶⁵]

The frequent presentation of dental malocclusions in patients with craniofacial birth defects also supports a strong genetic aetiology. About 150 genes are associated with craniofacial conditions presenting with malocclusions.[⁶⁶] Micrognathia is a commonly recurring craniofacial birth defect appearing among multiple syndromes.

For patients with severe malocclusions, corrective jaw surgery or orthognathic surgery may be carried out as a part of overall treatment, which can be seen in about 5% of the general population.[⁶²][⁶¹][⁶³]

See also

[edit]

- Crossbite
- Elastics
- Facemask (orthodontics)
- Maximum intercuspation
- Mouth breathing
- Occlusion (dentistry)

References

[edit]

1. ^ "malocclusion". *Oxford English Dictionary (Online ed.)*. Oxford University Press. (Subscription or participating institution membership required.)
2. ^ Bell B (September 1965). "Paul G. Spencer". *American Journal of Orthodontics*. **51** (9): 693–694. doi:10.1016/0002-9416(65)90262-9. PMID 14334001.
3. ^ Gruenbaum T (2010). "Famous Figures in Dentistry". *Mouth – JASDA*. **30** (1): 18.

4. ^ Hurt MA (2012). "Weedon D. Weedon's Skin Pathology. 3rd ed. London: Churchill Livingstone Elsevier, 2010". *Dermatology Practical & Conceptual*. **2** (1): 79–82. doi:10.5826/dpc.0201a15. PMC 3997252.
5. ^ Borzabadi-Farahani, A (2011). "An Overview of Selected Orthodontic Treatment Need Indices". In Naretto, Silvano (ed.). *Principles in Contemporary Orthodontics*. IntechOpen Limited. pp. 215–236. doi:10.5772/19735. ISBN 978-953-307-687-4.
6. ^ "How genetics can affect your teeth". *Orthodontics Australia*. 2018-11-25. Retrieved 2020-11-16.
7. ^ Corruccini RS, Potter RH (August 1980). "Genetic analysis of occlusal variation in twins". *American Journal of Orthodontics*. **78** (2): 140–54. doi:10.1016/0002-9416(80)90056-1. PMID 6931485.
8. ^ Sarig, Rachel; Slon, Viviane; Abbas, Janan; May, Hila; Shpack, Nir; Vardimon, Alexander Dan; HersHKovitz, Israel (2013-11-20). "Malocclusion in Early Anatomically Modern Human: A Reflection on the Etiology of Modern Dental Misalignment". *PLOS ONE*. **8** (11): e80771. Bibcode:2013PLoSO...880771S. doi:10.1371/journal.pone.0080771 . ISSN 1932-6203. PMC 3835570. PMID 24278319.
9. ^ Pajević, Tina; Juloski, Jovana; Glišić, Branislav (2019-08-29). "Malocclusion from the prehistoric to the medieval times in Serbian population: Dentoalveolar and skeletal relationship comparisons in samples". *Homo: Internationale Zeitschrift für die vergleichende Forschung am Menschen*. **70** (1): 31–43. doi:10.1127/homo/2019/1009. ISSN 1618-1301. PMID 31475289. S2CID 201203069.
10. ^ Moimaz SA, Garbin AJ, Lima AM, Lolli LF, Saliba O, Garbin CA (August 2014). "Longitudinal study of habits leading to malocclusion development in childhood". *BMC Oral Health*. **14** (1): 96. doi:10.1186/1472-6831-14-96. PMC 4126276. PMID 25091288.
11. ^ Klein ET (1952). "Pressure Habits, Etiological Factors in Malocclusion". *Am. J. Orthod*. **38** (8): 569–587. doi:10.1016/0002-9416(52)90025-0.
12. ^ Graber TM. (1963). "The "Three m's": Muscles, Malformation and Malocclusion". *Am. J. Orthod*. **49** (6): 418–450. doi:10.1016/0002-9416(63)90167-2. hdl:2027.42/32220. S2CID 57626540.
13. ^ Björk A, Helm S (April 1967). "Prediction of the age of maximum puberal growth in body height" (PDF). *The Angle Orthodontist*. **37** (2): 134–43. PMID 4290545.
14. ^ Brucker M (1943). "Studies on the Incidence and Cause of Dental Defects in Children: IV. Malocclusion" (PDF). *J Dent Res*. **22** (4): 315–321. doi:10.1177/00220345430220041201. S2CID 71368994.
15. ^ Calisti LJ, Cohen MM, Fales MH (1960). "Correlation between malocclusion, oral habits, and socio-economic level of preschool children". *Journal of Dental Research*. **39** (3): 450–4. doi:10.1177/00220345600390030501. PMID 13806967. S2CID 39619434.
16. ^ Subtelny JD, Subtelny JD (October 1973). "Oral habits--studies in form, function, and therapy". *The Angle Orthodontist*. **43** (4): 349–83. PMID 4583311.

17. ^ Aznar T, Galán AF, Marín I, Domínguez A (May 2006). "Dental arch diameters and relationships to oral habits". *The Angle Orthodontist*. **76** (3): 441–5. PMID 16637724.
18. ^ Yamaguchi H, Sueishi K (May 2003). "Malocclusion associated with abnormal posture". *The Bulletin of Tokyo Dental College*. **44** (2): 43–54. doi:10.2209/tdcpublication.44.43. PMID 12956088.
19. ^ Wellington M, Hall CB (February 2002). "Pacifier as a risk factor for acute otitis media". *Pediatrics*. **109** (2): 351–2, author reply 353. doi:10.1542/peds.109.2.351. PMID 11826228.
20. ^ Rovers MM, Numans ME, Langenbach E, Grobbee DE, Verheij TJ, Schilder AG (August 2008). "Is pacifier use a risk factor for acute otitis media? A dynamic cohort study". *Family Practice*. **25** (4): 233–6. doi:10.1093/fampra/cmn030. PMID 18562333.
21. ^ Hamish T (1990). *Occlusion*. Parkins, B. J. (2nd ed.). London: Wright. ISBN 978-0723620754. OCLC 21226656.
22. ^ Thilander B, Pena L, Infante C, Parada SS, de Mayorga C (April 2001). "Prevalence of malocclusion and orthodontic treatment need in children and adolescents in Bogota, Colombia. An epidemiological study related to different stages of dental development". *European Journal of Orthodontics*. **23** (2): 153–67. doi:10.1093/ejo/23.2.153. PMID 11398553.
23. ^ Borzabadi-Farahani A, Borzabadi-Farahani A, Eslamipour F (October 2009). "Malocclusion and occlusal traits in an urban Iranian population. An epidemiological study of 11- to 14-year-old children". *European Journal of Orthodontics*. **31** (5): 477–84. doi:10.1093/ejo/cjp031. PMID 19477970.
24. ^ "5 reasons you should see an orthodontist". *Orthodontics Australia*. 2017-09-27. Retrieved 2020-08-18.
25. ^ **a b c** Oliver RG (December 2001). "An Introduction to Orthodontics, 2nd edn". *Journal of Orthodontics*. **28** (4): 320. doi:10.1093/ortho/28.4.320.
26. ^ **a b c** Millett DT, Cunningham SJ, O'Brien KD, Benson PE, de Oliveira CM (February 2018). "Orthodontic treatment for deep bite and retroclined upper front teeth in children". *The Cochrane Database of Systematic Reviews*. **2** (3): CD005972. doi:10.1002/14651858.cd005972.pub4. PMC 6491166. PMID 29390172.
27. ^ Brunelle JA, Bhat M, Lipton JA (February 1996). "Prevalence and distribution of selected occlusal characteristics in the US population, 1988-1991". *Journal of Dental Research*. 75 Spec No (2 Suppl): 706–13. doi:10.1177/002203459607502S10. PMID 8594094. S2CID 30447284.
28. ^ de Castilho LS, Abreu MH, Pires e Souza LG, Romualdo LT, Souza e Silva ME, Resende VL (January 2018). "Factors associated with anterior open bite in children with developmental disabilities". *Special Care in Dentistry*. **38** (1): 46–50. doi:10.1111/scd.12262. PMID 29278267. S2CID 42747680.

29. ^ Feres MF, Abreu LG, Insabralde NM, Almeida MR, Flores-Mir C (June 2016). "Effectiveness of the open bite treatment in growing children and adolescents. A systematic review". *European Journal of Orthodontics*. **38** (3): 237–50. doi:10.1093/ejo/cjv048. PMC 4914905. PMID 26136439.
30. ^ **a b** Cambiano AO, Janson G, Lorenzoni DC, Garib DG, Dávalos DT (2018). "Nonsurgical treatment and stability of an adult with a severe anterior open-bite malocclusion". *Journal of Orthodontic Science*. **7**: 2. doi:10.4103/jos.JOS_69_17. PMC 5952238. PMID 29765914.
31. ^ Houston, W. J. B. (1992-02-01). "Book Reviews". *The European Journal of Orthodontics* . **14** (1): 69. doi:10.1093/ejo/14.1.69.
32. ^ Hamdan AM, Lewis SM, Kelleher KE, Elhady SN, Lindauer SJ (November 2019). "Does overbite reduction affect smile esthetics?". *The Angle Orthodontist*. **89** (6): 847–854. doi: 10.2319/030819-177.1. PMC 8109173. PMID 31306077.
33. ^ "Angle's Classification of Malocclusion". Archived from the original on 2008-02-13. Retrieved 2007-10-31.
34. ^ Sunil Kumar (Ed.): Orthodontics. New Delhi 2008, 624 p., ISBN 978-81-312-1054-3, p. 127
35. ^ Sunil Kumar (Ed.): Orthodontics. New Delhi 2008, p. 123. A list of 18 approaches to modify or replace Angle's system is given here with further references at the end of the book.
36. ^ Gurkeerat Singh: Textbook of Orthodontics, p. 163–170, with further references on p. 174.
37. ^ **a b c d** Lieberman, D (May 2004). "Effects of food processing on masticatory strain and craniofacial growth in a retrognathic face". *Journal of Human Evolution*. **46** (6): 655–77. doi:10.1016/s0047-2484(04)00051-x. PMID 15183669.
38. ^ **a b** Ingervall B, Bitsanis E (February 1987). "A pilot study of the effect of masticatory muscle training on facial growth in long-face children" (PDF). *European Journal of Orthodontics*. **9** (1): 15–23. doi:10.1093/ejo/9.1.15. PMID 3470182.
39. ^ **a b** Rosenberg J (2010-02-22). "Malocclusion of teeth". *Medline Plus*. Retrieved 2012-02-06.
40. ^ Victora CG, Bahl R, Barros AJ, França GV, Horton S, Krasevec J, Murch S, Sankar MJ, Walker N, Rollins NC (January 2016). "Breastfeeding in the 21st century: epidemiology, mechanisms, and lifelong effect". *Lancet*. **387** (10017): 475–90. doi:10.1016/s0140-6736(15)01024-7. PMID 26869575.
41. ^ Quaglio CL, de Freitas KM, de Freitas MR, Janson G, Henriques JF (June 2011). "Stability and relapse of maxillary anterior crowding treatment in class I and class II Division 1 malocclusions". *American Journal of Orthodontics and Dentofacial Orthopedics*.

139 (6): 768–74. doi:10.1016/j.ajodo.2009.10.044. PMID 21640883.

42. ^ **a b** "Dental Crowding: Causes and Treatment Options". Orthodontics Australia. 2020-06-29. Retrieved 2020-11-19.
43. ^ "Malocclusion of teeth: MedlinePlus Medical Encyclopedia". medlineplus.gov. Retrieved 2021-04-07.
44. ^ "Can Buck Teeth Be Fixed? Causes & Treatment Options". Orthodontics Australia. 2021-07-01. Retrieved 2021-10-11.
45. ^ **a b** Alam, MK (October 2018). "Treatment of Angle Class I malocclusion with severe crowding by extraction of four premolars: a case report". *Bangladesh Journal of Medical Science*. **17** (4): 683–687. doi:10.3329/bjms.v17i4.38339.
46. ^ Persson M, Persson EC, Skagius S (August 1989). "Long-term spontaneous changes following removal of all first premolars in Class I cases with crowding". *European Journal of Orthodontics*. **11** (3): 271–82. doi:10.1093/oxfordjournals.ejo.a035995. PMID 2792216.
47. ^ von Cramon-Taubadel N (December 2011). "Global human mandibular variation reflects differences in agricultural and hunter-gatherer subsistence strategies". *Proceedings of the National Academy of Sciences of the United States of America*. **108** (49): 19546–51. Bibcode:2011PNAS..10819546V. doi:10.1073/pnas.1113050108. PMC 3241821. PMID 22106280.
48. ^ Nayak KU, Goyal V, Malviya N (October 2011). "Two-phase treatment of class II malocclusion in young growing patient". *Contemporary Clinical Dentistry*. **2** (4): 376–80. doi:10.4103/0976-237X.91808. PMC 3276872. PMID 22346172.
49. ^ "Treatment of class ii malocclusions". 2013-11-14.
50. ^ **a b c** Pinhasi R, Eshed V, von Cramon-Taubadel N (2015-02-04). "Incongruity between affinity patterns based on mandibular and lower dental dimensions following the transition to agriculture in the Near East, Anatolia and Europe". *PLOS ONE*. **10** (2): e0117301. Bibcode:2015PLoSO..1017301P. doi:10.1371/journal.pone.0117301. PMC 4317182. PMID 25651540.
51. ^ **a b c d** Batista KB, Thiruvengkatachari B, Harrison JE, O'Brien KD (March 2018). "Orthodontic treatment for prominent upper front teeth (Class II malocclusion) in children and adolescents". *The Cochrane Database of Systematic Reviews*. **2018** (3): CD003452. doi:10.1002/14651858.cd003452.pub4. PMC 6494411. PMID 29534303.
52. ^ CLASSIFICATION OF SKELETAL AND DENTAL MALOCCLUSION: REVISITED; Mageet, Adil Osman (2016). "Classification of Skeletal and Dental Malocclusion: Revisited". *Stomatology Edu Journal*. **3** (2): 205–211. doi:10.25241/2016.3(2).11.
53. ^ *Esthetics and biomechanics in orthodontics*. Nanda, Ravindra,, Preceded by (work): Nanda, Ravindra. (Second ed.). St. Louis, Missouri. 2014-04-10. ISBN 978-0-323-22659-2. OCLC 880707123.cite book: CS1 maint: location missing publisher (link) CS1 maint: others (link)

54. ^ Eslami S, Faber J, Fateh A, Sheikholaemmeh F, Grassia V, Jamilian A (August 2018). "Treatment decision in adult patients with class III malocclusion: surgery versus orthodontics". *Progress in Orthodontics*. **19** (1): 28. doi:10.1186/s40510-018-0218-0. PMC 6070451. PMID 30069814.
55. ^ **a b** Uner O, Yüksel S, Uçüncü N (April 1995). "Long-term evaluation after chincap treatment". *European Journal of Orthodontics*. **17** (2): 135–41. doi:10.1093/ejo/17.2.135. PMID 7781722.
56. ^ Ravi MS, Shetty NK, Prasad RB (January 2012). "Orthodontics-surgical combination therapy for Class III skeletal malocclusion". *Contemporary Clinical Dentistry*. **3** (1): 78–82. doi:10.4103/0976-237X.94552. PMC 3341765. PMID 22557903.
57. ^ Borzabadi Farahani A, Olkun HK, Eslamian L, Eslamipour F (2024). "A retrospective investigation of orthognathic patients and functional needs". *Australasian Orthodontic Journal*. **40**: 111–120. doi:10.2478/aoj-2024-0013.
58. ^ **a b** Atsawasuwan P, Hohlt W, Evans CA (April 2015). "Nonsurgical approach to Class I open-bite malocclusion with extrusion mechanics: a 3-year retention case report". *American Journal of Orthodontics and Dentofacial Orthopedics*. **147** (4): 499–508. doi:10.1016/j.ajodo.2014.04.024. PMID 25836010.
59. ^ **a b** Grauer D, Heymann GC, Swift EJ (June 2012). "Clinical management of tooth size discrepancies". *Journal of Esthetic and Restorative Dentistry*. **24** (3): 155–9. doi:10.1111/j.1708-8240.2012.00520.x. PMID 22691075. S2CID 11482185.
60. ^ **a b** Cançado RH, Gonçalves Júnior W, Valarelli FP, Freitas KM, Crêspo JA (2015). "Association between Bolton discrepancy and Angle malocclusions". *Brazilian Oral Research*. **29**: 1–6. doi:10.1590/1807-3107BOR-2015.vol29.0116. PMID 26486769.
61. ^ **a b c** Harrington C, Gallagher JR, Borzabadi-Farahani A (July 2015). "A retrospective analysis of dentofacial deformities and orthognathic surgeries using the index of orthognathic functional treatment need (IOFTN)". *International Journal of Pediatric Otorhinolaryngology*. **79** (7): 1063–6. doi:10.1016/j.ijporl.2015.04.027. PMID 25957779.
62. ^ **a b c d** Posnick JC (September 2013). "Definition and Prevalence of Dentofacial Deformities". *Orthognathic Surgery: Principles and Practice*. Amsterdam: Elsevier. pp. 61–68. doi:10.1016/B978-1-4557-2698-1.00003-4. ISBN 978-145572698-1.
63. ^ **a b c** Borzabadi-Farahani A, Eslamipour F, Shahmoradi M (June 2016). "Functional needs of subjects with dentofacial deformities: A study using the index of orthognathic functional treatment need (IOFTN)". *Journal of Plastic, Reconstructive & Aesthetic Surgery*. **69** (6): 796–801. doi:10.1016/j.bjps.2016.03.008. PMID 27068664.
64. ^ Purkait, S (2011). *Essentials of Oral Pathology 4th Edition*.
65. ^ Joshi N, Hamdan AM, Fakhouri WD (December 2014). "Skeletal malocclusion: a developmental disorder with a life-long morbidity". *Journal of Clinical Medicine Research*. **6** (6): 399–408. doi:10.14740/jocmr1905w. PMC 4169080. PMID 25247012.

66. ^ Moreno Uribe LM, Miller SF (April 2015). "Genetics of the dentofacial variation in human malocclusion". *Orthodontics & Craniofacial Research*. 18 Suppl 1 (S1): 91–9. doi:10.1111/ocr.12083. PMC 4418210. PMID 25865537.

Further reading

[edit]

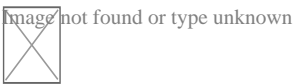
- Peter S. Ungar, "The Trouble with Teeth: Our teeth are crowded, crooked and riddled with cavities. It hasn't always been this way", *Scientific American*, vol. 322, no. 4 (April 2020), pp. 44–49. "Our teeth [...] evolved over hundreds of millions of years to be incredibly strong and to align precisely for efficient chewing. [...] Our dental disorders largely stem from a shift in the oral environment caused by the introduction of softer, more sugary foods than the ones our ancestors typically ate."

External links

[edit]

Classification

- **ICD-10:** K07.3, K07.4, K07.5, K07.6
- **ICD-9-CM:** 524.4
- **MeSH:** D008310



Wikimedia Commons has media related to **Malocclusion**.

- v
- t
- e

Orthodontics

Diagnosis

- Bolton analysis
- Cephalometric analysis
- Cephalometry
- Dentition analysis
- Failure of eruption of teeth
- Little's Irregularity Index
- Malocclusion
- Scissor bite
- Standard anatomical position
- Tooth ankylosis
- Tongue thrust

Conditions

- Overbite
- Overjet
- Open bite
- Crossbite
- Dental crowding
- Dental spacing
- Bimaxillary Protrusion
- Prognathism
- Retrognathism
- Maxillary hypoplasia
- Condylar hyperplasia
- Overeruption
- Mouth breathing
- Temporomandibular dysfunction

- ACCO appliance
- Archwire
- Activator appliance
- Braces
- Damon system
- Elastics
- Frankel appliance
- Invisalign
- Lingual arch
- Lip bumper
- Herbst Appliance
- List of orthodontic functional appliances

Appliances

- List of palatal expanders
- Lingual braces
- Headgear
- Orthodontic technology
- Orthodontic spacer
- Palatal lift prosthesis
- Palatal expander
- Quad helix
- Retainer
- SureSmile
- Self-ligating braces
- Splint activator
- Twin Block Appliance

Procedures

- Anchorage (orthodontics)
- Cantilever mechanics
- Fiberotomy
- Interproximal reduction
- Intrusion (orthodontics)
- Molar distalization
- SARPE
- Serial extraction

Materials

- Beta-titanium
- Nickel titanium
- Stainless steel
- TiMolium
- Elgiloy
- Ceramic
- Composite
- Dental elastics

- Edward Angle
- Spencer Atkinson
- Clifford Ballard
- Raymond Begg
- Hans Peter Bimler
- Samir Bishara
- Arne Björk
- Charles B. Bolton
- Holly Broadbent Sr.
- Allan G. Brodie
- Charles J. Burstone
- Peter Buschang
- Calvin Case
- Harold Chapman (Orthodontist)
- David Di Biase
- Jean Delaire
- Terry Dischinger
- William B. Downs
- John Nutting Farrar
- Rolf Frankel
- Sheldon Friel
- Thomas M. Graber
- Charles A. Hawley
- Reed Holdaway
- John Hooper (Orthodontist)
- Joseph Jarabak
- Harold Kesling
- Albert Ketcham
- Juri Kurol
- Craven Kurz
- Benno Lischer
- James A. McNamara
- Birte Melsen
- Robert Moyers
- Hayes Nance

**Notable
contributors**

Organizations	○ American Association of Orthodontists
	○ American Board of Orthodontics
	○ British Orthodontic Society
	○ Canadian Association of Orthodontists
	○ Indian Orthodontic Society
	○ Italian Academy of Orthodontic Technology
Journals	○ Society for Orthodontic Dental Technology (Germany)
	○ American Journal of Orthodontics and Dentofacial Orthopedics
	○ The Angle Orthodontist
	○ Journal of Orthodontics
Institution	○ Angle School of Orthodontia

- v
- t
- e

Dental disease involving the jaw

General	○ Jaw abnormality
	○ malocclusion
	○ Orthodontics
	○ Gnathitis
Size	○ Micrognathism
	○ Maxillary hypoplasia

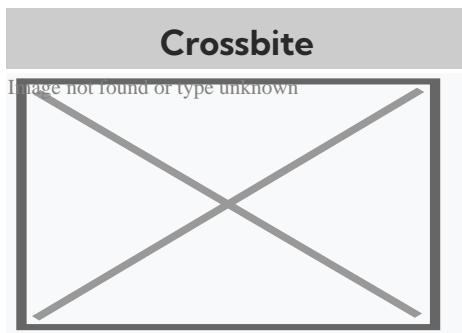
Maxilla and Mandible

- Cherubism
- Congenital epulis
- Torus mandibularis
- Torus palatinus

Other

- Jaw and base of cranium
 - Prognathism
 - Retrognathism
- Dental arch
 - Crossbite
 - Overbite
- Temporomandibular joint disorder

About crossbite




Unilateral posterior crossbite

Specialty Orthodontics

In dentistry, **crossbite** is a form of malocclusion where a tooth (or teeth) has a more buccal or lingual position (that is, the tooth is either closer to the cheek or to the tongue) than its corresponding antagonist tooth in the upper or lower dental arch. In other words, crossbite is a lateral misalignment of the dental arches.^{[1][2]}

Anterior crossbite

[edit]



Class 1 with anterior crossbite

An anterior crossbite can be referred as negative overjet, and is typical of class III skeletal relations (prognathism).

Primary/mixed dentitions

[edit]

An anterior crossbite in a child with baby teeth or mixed dentition may happen due to either dental misalignment or skeletal misalignment. Dental causes may be due to displacement of one or two teeth, where skeletal causes involve either mandibular hyperplasia, maxillary hypoplasia or combination of both.

Dental crossbite

[edit]

An anterior crossbite due to dental component involves displacement of either maxillary central or lateral incisors lingual to their original erupting positions. This may happen due to delayed eruption of the primary teeth leading to permanent teeth moving lingual to their primary predecessors. This will lead to anterior crossbite where upon biting, upper teeth are behind the lower front teeth and may involve few or all frontal incisors. In this type of

crossbite, the maxillary and mandibular proportions are normal to each other and to the cranial base. Another reason that may lead to a dental crossbite is crowding in the maxillary arch. Permanent teeth will tend to erupt lingual to the primary teeth in presence of crowding. Side-effects caused by dental crossbite can be increased recession on the buccal of lower incisors and higher chance of inflammation in the same area. Another term for an anterior crossbite due to dental interferences is *Pseudo Class III Crossbite or Malocclusion*.

Single tooth crossbite

[edit]

Single tooth crossbites can occur due to uneruption of a primary teeth in a timely manner which causes permanent tooth to erupt in a different eruption pattern which is lingual to the primary tooth.^[3] Single tooth crossbites are often fixed by using a finger-spring based appliances.^[4]^[5] This type of spring can be attached to a removable appliance which is used by patient every day to correct the tooth position.

Skeletal crossbite

[edit]

An anterior crossbite due to skeletal reasons will involve a deficient maxilla and a more hyperplastic or overgrown mandible. People with this type of crossbite will have dental compensation which involves proclined maxillary incisors and retroclined mandibular incisors. A proper diagnosis can be made by having a person bite into their centric relation will show mandibular incisors ahead of the maxillary incisors, which will show the skeletal discrepancy between the two jaws.^[6]

Posterior crossbite

[edit]

Bjork defined posterior crossbite as a malocclusion where the buccal cusps of canine, premolar and molar of upper teeth occlude lingually to the buccal cusps of canine, premolar and molar of lower teeth.^[7] Posterior crossbite is often correlated to a narrow maxilla and upper dental arch. A posterior crossbite can be unilateral, bilateral, single-tooth or entire segment crossbite. Posterior crossbite has been reported to occur between 7–23% of the population.^[8]^[9] The most common type of posterior crossbite to occur is the unilateral crossbite which occurs in 80% to 97% of the posterior crossbite cases.^[10]^[3] Posterior crossbites also occur most commonly in primary and mixed dentition. This type of crossbite usually presents with a *functional shift of the mandible towards the side of the crossbite*. Posterior crossbite can occur due to either skeletal, dental or functional abnormalities. One of the common reasons for development of posterior crossbite is the size difference between maxilla and mandible, where maxilla is smaller than mandible.^[11] Posterior crossbite can result due to

- Upper Airway Obstruction where people with "adenoid faces" who have trouble breathing through their nose. They have an open bite malocclusion and present with development of posterior crossbite.^[12]
- Prolong digit or suckling habits which can lead to constriction of maxilla posteriorly^[13]
- Prolong pacifier use (beyond age 4)^[13]

Connections with TMD

[edit]

Unilateral posterior crossbite

[edit]

Unilateral crossbite involves one side of the arch. The most common cause of unilateral crossbite is a narrow maxillary dental arch. This can happen due to habits such as digit sucking, prolonged use of pacifier or upper airway obstruction. Due to the discrepancy between the maxillary and mandibular arch, neuromuscular guidance of the mandible causes mandible to shift towards the side of the crossbite.^[14] This is also known as

Functional mandibular shift. This shift can become structural if left untreated for a long time during growth, leading to skeletal asymmetries. Unilateral crossbites can present with following features in a child

- Lower midline deviation^[15] to the crossbite side
- Class 2 Subdivision relationships
- Temporomandibular disorders ^[16]

Treatment

[edit]

A child with posterior crossbite should be treated immediately if the child shifts their mandible on closing, which is often seen in a unilateral crossbite as mentioned above. The best age to treat a child with crossbite is in their mixed dentition when their palatal sutures have not fused to each other. Palatal expansion allows more space in an arch to relieve crowding and correct posterior crossbite. The correction can include any type of palatal expanders that will expand the palate which resolves the narrow constriction of the maxilla.^[9] There are several therapies that can be used to correct a posterior crossbite: braces, 'Z' spring or cantilever spring, quad helix, removable plates, clear aligner therapy, or a Delaire mask. The correct therapy should be decided by the orthodontist depending on the type and severity of the crossbite.

One of the keys in diagnosing the anterior crossbite due to skeletal vs dental causes is diagnosing a CR-CO shift in a patient. An adolescent presenting with anterior crossbite may be positioning their mandible forward into centric occlusion (CO) due to the dental interferences. Thus finding their occlusion in centric relation (CR) is key in diagnosis. For anterior crossbite, if their CO matches their CR then the patient truly has a skeletal component to their crossbite. If the CR shows a less severe class 3 malocclusion or teeth not in anterior crossbite, this may mean that their anterior crossbite results due to dental interferences.^[17]

Goal to treat unilateral crossbites should definitely include removal of occlusal interferences and elimination of the functional shift. Treating posterior crossbites early

may help prevent the occurrence of Temporomandibular joint pathology.^[18]

Unilateral crossbites can also be diagnosed and treated properly by using a Deprogramming splint. This splint has flat occlusal surface which causes the muscles to deprogram themselves and establish new sensory engrams. When the splint is removed, a proper centric relation bite can be diagnosed from the bite.^[19]

Self-correction

[edit]

Literature states that very few crossbites tend to self-correct which often justify the treatment approach of correcting these bites as early as possible.^[9] Only 0–9% of crossbites self-correct. Lindner et al. reported that 50% of crossbites were corrected in 76 four-year-old children.^[20]

See also

[edit]

- List of palatal expanders
- Palatal expansion
- Malocclusion

References

[edit]

- [^] "Elsevier: Proffit: Contemporary Orthodontics · Welcome". *www.contemporaryorthodontics.com*. Retrieved 2016-12-11.
- [^] Borzabadi-Farahani A, Borzabadi-Farahani A, Eslamipour F (October 2009). "Malocclusion and occlusal traits in an urban Iranian population. An epidemiological study of 11- to 14-year-old children". *European Journal of Orthodontics*. **31** (5): 477–84. doi:10.1093/ejo/cjp031. PMID 19477970.

3. ^ **a b** Kutin, George; Hawes, Roland R. (1969-11-01). "Posterior cross-bites in the deciduous and mixed dentitions". *American Journal of Orthodontics*. **56** (5): 491–504. doi:10.1016/0002-9416(69)90210-3. PMID 5261162.
4. ^ Zietsman, S. T.; Visagé, W.; Coetzee, W. J. (2000-11-01). "Palatal finger springs in removable orthodontic appliances--an in vitro study". *South African Dental Journal*. **55** (11): 621–627. ISSN 1029-4864. PMID 12608226.
5. ^ Ulusoy, Ayca Tuba; Bodrumlu, Ebru Hazar (2013-01-01). "Management of anterior dental crossbite with removable appliances". *Contemporary Clinical Dentistry*. **4** (2): 223–226. doi:10.4103/0976-237X.114855. ISSN 0976-237X. PMC 3757887. PMID 24015014.
6. ^ Al-Hummayani, Fadia M. (2017-03-05). "Pseudo Class III malocclusion". *Saudi Medical Journal*. **37** (4): 450–456. doi:10.15537/smj.2016.4.13685. ISSN 0379-5284. PMC 4852025. PMID 27052290.
7. ^ Bjoerk, A.; Krebs, A.; Solow, B. (1964-02-01). "A Method for Epidemiological Registration of Malocclusion". *Acta Odontologica Scandinavica*. **22**: 27–41. doi:10.3109/00016356408993963. ISSN 0001-6357. PMID 14158468.
8. ^ Moyers, Robert E. (1988-01-01). *Handbook of orthodontics*. Year Book Medical Publishers. ISBN 9780815160038.
9. ^ **a b c** Thilander, Birgit; Lennartsson, Bertil (2002-09-01). "A study of children with unilateral posterior crossbite, treated and untreated, in the deciduous dentition--occlusal and skeletal characteristics of significance in predicting the long-term outcome". *Journal of Orofacial Orthopedics*. **63** (5): 371–383. doi:10.1007/s00056-002-0210-6. ISSN 1434-5293. PMID 12297966. S2CID 21857769.
10. ^ Thilander, Birgit; Wahlund, Sonja; Lennartsson, Bertil (1984-01-01). "The effect of early interceptive treatment in children with posterior cross-bite". *The European Journal of Orthodontics*. **6** (1): 25–34. doi:10.1093/ejo/6.1.25. ISSN 0141-5387. PMID 6583062.
11. ^ Allen, David; Rebellato, Joe; Sheats, Rose; Ceron, Ana M. (2003-10-01). "Skeletal and dental contributions to posterior crossbites". *The Angle Orthodontist*. **73** (5): 515–524. ISSN 0003-3219. PMID 14580018.
12. ^ Bresolin, D.; Shapiro, P. A.; Shapiro, G. G.; Chapko, M. K.; Dassel, S. (1983-04-01). "Mouth breathing in allergic children: its relationship to dentofacial development". *American Journal of Orthodontics*. **83** (4): 334–340. doi:10.1016/0002-9416(83)90229-4. ISSN 0002-9416. PMID 6573147.
13. ^ **a b** Ogaard, B.; Larsson, E.; Lindsten, R. (1994-08-01). "The effect of sucking habits, cohort, sex, intercanine arch widths, and breast or bottle feeding on posterior crossbite in Norwegian and Swedish 3-year-old children". *American Journal of Orthodontics and Dentofacial Orthopedics*. **106** (2): 161–166. doi:10.1016/S0889-5406(94)70034-6. ISSN 0889-5406. PMID 8059752.
14. ^ Piancino, Maria Grazia; Kyrkanides, Stephanos (2016-04-18). *Understanding Masticatory Function in Unilateral Crossbites*. John Wiley & Sons. ISBN 9781118971871.

15. ^ Brin, Ilana; Ben-Bassat, Yocheved; Blustein, Yoel; Ehrlich, Jacob; Hochman, Nira; Marmary, Yitzhak; Yaffe, Avinoam (1996-02-01). "Skeletal and functional effects of treatment for unilateral posterior crossbite". *American Journal of Orthodontics and Dentofacial Orthopedics*. **109** (2): 173–179. doi:10.1016/S0889-5406(96)70178-6. PMID 8638566.
16. ^ Pullinger, A. G.; Seligman, D. A.; Gornbein, J. A. (1993-06-01). "A multiple logistic regression analysis of the risk and relative odds of temporomandibular disorders as a function of common occlusal features". *Journal of Dental Research*. **72** (6): 968–979. doi:10.1177/00220345930720061301. ISSN 0022-0345. PMID 8496480. S2CID 25351006.
17. ^ COSTEA, CARMEN MARIA; BADEA, MÎNDRA EUGENIA; VASILACHE, SORIN; MESAROAIA, MICHAELA (2016-01-01). "Effects of CO-CR discrepancy in daily orthodontic treatment planning". *Clujul Medical*. **89** (2): 279–286. doi:10.15386/cjmed-538. ISSN 1222-2119. PMC 4849388. PMID 27152081.
18. ^ Kennedy, David B.; Osepchook, Matthew (2005-09-01). "Unilateral posterior crossbite with mandibular shift: a review". *Journal (Canadian Dental Association)*. **71** (8): 569–573. ISSN 1488-2159. PMID 16202196.
19. ^ Nielsen, H. J.; Bakke, M.; Blixencrone-Møller, T. (1991-12-01). "[Functional and orthodontic treatment of a patient with an open bite craniomandibular disorder]". *Tandlaegebladet*. **95** (18): 877–881. ISSN 0039-9353. PMID 1817382.
20. ^ Lindner, A. (1989-10-01). "Longitudinal study on the effect of early interceptive treatment in 4-year-old children with unilateral cross-bite". *Scandinavian Journal of Dental Research*. **97** (5): 432–438. doi:10.1111/j.1600-0722.1989.tb01457.x. ISSN 0029-845X. PMID 2617141.

External links

[edit]

Classification

D

- **ICD-10:** K07.2
- **ICD-9-CM:** 524.27

- v
- t
- e

Orthodontics

Diagnosis

- Bolton analysis
- Cephalometric analysis
- Cephalometry
- Dentition analysis
- Failure of eruption of teeth
- Little's Irregularity Index
- Malocclusion
- Scissor bite
- Standard anatomical position
- Tooth ankylosis
- Tongue thrust

Conditions

- Overbite
- Overjet
- Open bite
- Crossbite
- Dental crowding
- Dental spacing
- Bimaxillary Protrusion
- Prognathism
- Retrognathism
- Maxillary hypoplasia
- Condylar hyperplasia
- Overeruption
- Mouth breathing
- Temporomandibular dysfunction

- ACCO appliance
- Archwire
- Activator appliance
- Braces
- Damon system
- Elastics
- Frankel appliance
- Invisalign
- Lingual arch
- Lip bumper
- Herbst Appliance
- List of orthodontic functional appliances

Appliances

- List of palatal expanders
- Lingual braces
- Headgear
- Orthodontic technology
- Orthodontic spacer
- Palatal lift prosthesis
- Palatal expander
- Quad helix
- Retainer
- SureSmile
- Self-ligating braces
- Splint activator
- Twin Block Appliance

Procedures

- Anchorage (orthodontics)
- Cantilever mechanics
- Fiberotomy
- Interproximal reduction
- Intrusion (orthodontics)
- Molar distalization
- SARPE
- Serial extraction

Materials

- Beta-titanium
- Nickel titanium
- Stainless steel
- TiMolium
- Elgiloy
- Ceramic
- Composite
- Dental elastics

- Edward Angle
- Spencer Atkinson
- Clifford Ballard
- Raymond Begg
- Hans Peter Bimler
- Samir Bishara
- Arne Björk
- Charles B. Bolton
- Holly Broadbent Sr.
- Allan G. Brodie
- Charles J. Burstone
- Peter Buschang
- Calvin Case
- Harold Chapman (Orthodontist)
- David Di Biase
- Jean Delaire
- Terry Dischinger
- William B. Downs
- John Nutting Farrar
- Rolf Frankel
- Sheldon Friel
- Thomas M. Graber
- Charles A. Hawley
- Reed Holdaway
- John Hooper (Orthodontist)
- Joseph Jarabak
- Harold Kesling
- Albert Ketcham
- Juri Kurol
- Craven Kurz
- Benno Lischer
- James A. McNamara
- Birte Melsen
- Robert Moyers
- Hayes Nance

**Notable
contributors**

Organizations

- American Association of Orthodontists
- American Board of Orthodontics
- British Orthodontic Society
- Canadian Association of Orthodontists
- Indian Orthodontic Society
- Italian Academy of Orthodontic Technology
- Society for Orthodontic Dental Technology (Germany)

Journals

- American Journal of Orthodontics and Dentofacial Orthopedics
- The Angle Orthodontist
- Journal of Orthodontics

Institution

- Angle School of Orthodontia

- v
- t
- e

Dental disease involving the jaw

General

- Jaw abnormality
- malocclusion
- Orthodontics
- Gnathitis

Size

- Micrognathism
- Maxillary hypoplasia

Maxilla and Mandible

- Cherubism
- Congenital epulis
- Torus mandibularis
- Torus palatinus

Other

- Jaw and base of cranium
 - Prognathism
 - Retrognathism
- Dental arch
 - Crossbite
 - Overbite
- Temporomandibular joint disorder

Authority control databases: **National**  **Germany**
Edit this at Wikidata

Check our other pages :

- [Approaches to Early Interceptive Orthodontics](#)
- [Examining Crossbites and Jaw Alignment](#)
- [Observing Bite Patterns for Early Intervention Strategies](#)
- [Regular Adjustments and Why They Matter](#)
- [Comparing Lingual Braces and External Options](#)

IQDENT – Ortodontska Klinika

Phone : +385953817015

City : Zagreb

State : Hrvatska

Zip : 10000

Address : IQDENT – Ortodontska Klinika

Company Website : <https://iqdent.hr/>

USEFUL LINKS

[Orthodontic treatment can help improve your child's smile](#)

[Orthodontic treatment for children](#)

[Sitemap](#)

[Privacy Policy](#)

[About Us](#)

Follow us